

HISTOPATHOLOGY REPORT



H11-XXXX

REPORT INFORMATION

Collected Date: 01-Dec-2009
Received Date: 04-Dec-2009
Reported Date: 09-Dec-2009

PATIENT INFORMATION

DOE, JANE
Date of Birth: 09-Jul-1950
Age: 59
Gender: F
Medical #: 123456789
Patient ID #:

PHYSICIAN INFORMATION

Referring Physician: JOHN DOE
Medical #: 54321
Phone #: 604-123-4567 Fax #: 604-765-4321
Street:
City: Vancouver Province/State: BC
Country: Canada Postal Code:
Additional Physician:

DIAGNOSIS

A: RECTUM, MASS BIOPSY - INVASIVE MODERATELY DIFFERENTIATED ADENOCARCINOMA - SEE COMMENT.

Electronically Signed by: Dr. Pathologist 09-Dec-2009 08:23 PM PST

COMMENTS

The sections show ulceration of the mucosa associated with an invasive moderately differentiated adenocarcinoma of large bowel. The depth of invasion cannot be assessed in this material.

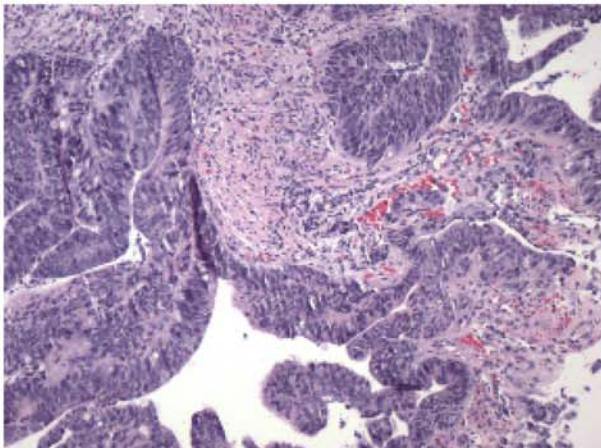


Figure 1: A1 H&E /1

A: Bx Rectal mass - Adenocarcinoma

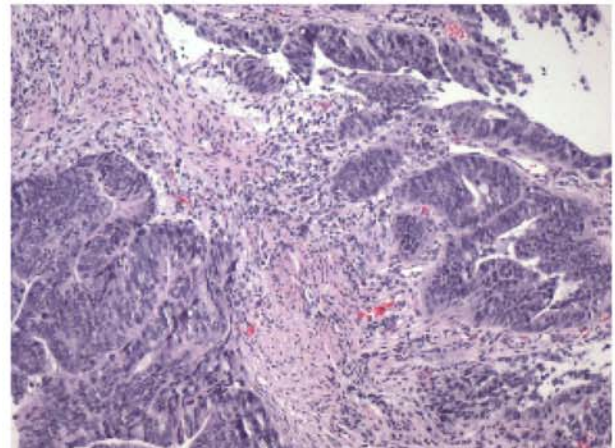


Figure 2: A1 H&E /2

A: Bx Mass Rectum - Adenocarcinoma

Pathologist: PATH 09-Dec-2009 08:23 PM PST

CLINICAL SUMMARY

Hx of DBM
Large mass in rectum

SPECIMEN DESCRIPTION

Specimen A: Bx Mass Rectum

Collected By:



GROSS DESCRIPTION

Specimen "H11-XXXX" is received in 1 container, labeled with patient's name " Jane Doe " and "Bx. Mass Rectum". The specimen was taken on Dec 1, 2009 and received in buffered formalin on Dec 4, 2009 . The specimen consists of multiple pale tan tissue fragments, aggregating to 8mm in greatest diameter. The specimen is submitted entirely in block A1.

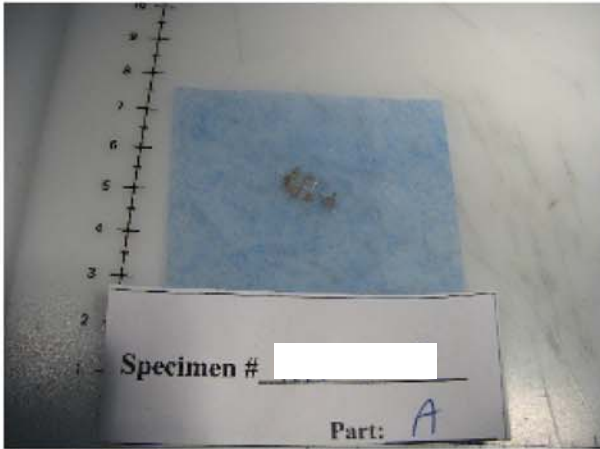

Figure 3: Grossing Image, H11-XXXX

Histotechnologist/Pathologist: Tech 08-Dec-2009 09:51 AM PST